# Disorder of the dental pulp
# Pulpitis

**Pulp tissue** is composed of delicate C.T. , blood vessels , lymphatics , myelinated & unmyelinated nerve fibers & undifferentiated cells. like other connective tissues throughout the body; it reacts to noxious stimuli by an inflammatory response

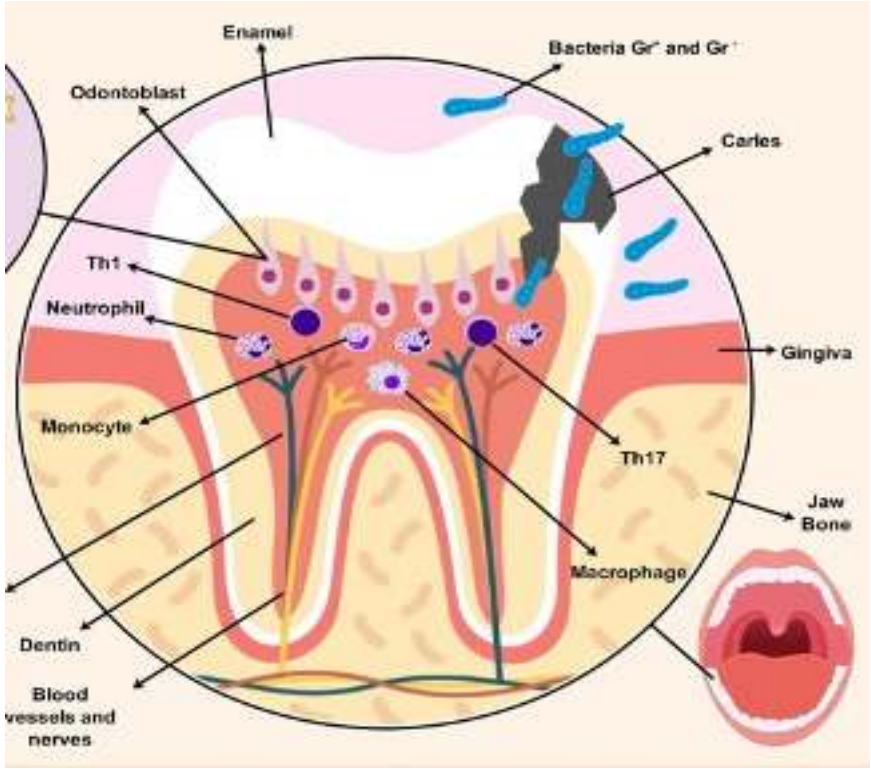

Reversible pulpitis denotes a level of pulpal inflammation in which the tissue is capable of returning to a normal state of health if the noxious stimuli are removed.

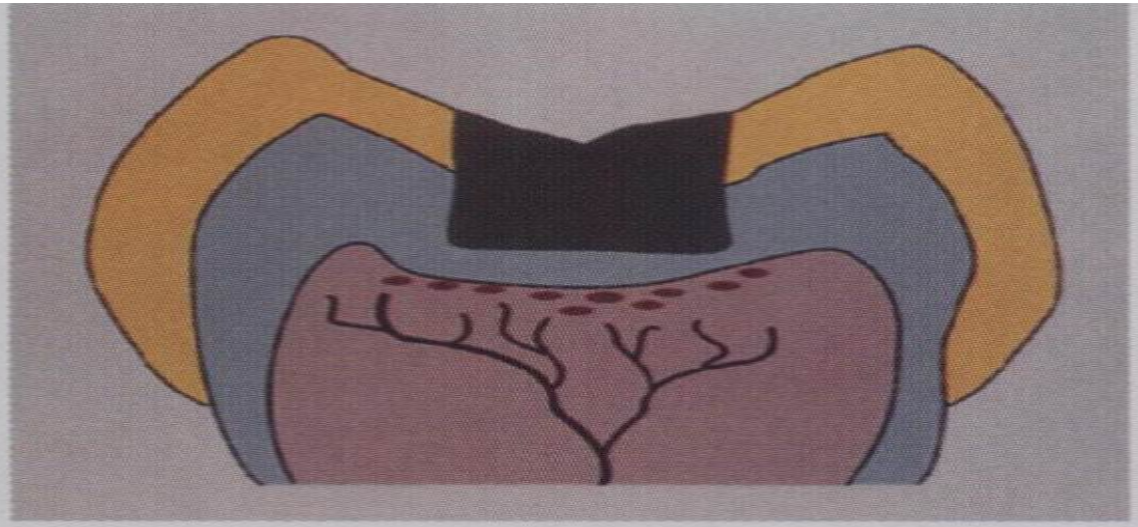

**FIGURE 3-13**

**Reversible pulpitis.** Diagram of mild transient pulpal inflammation that occurs immediately after the placement of a deep restoration.

# Reversible pulpitis

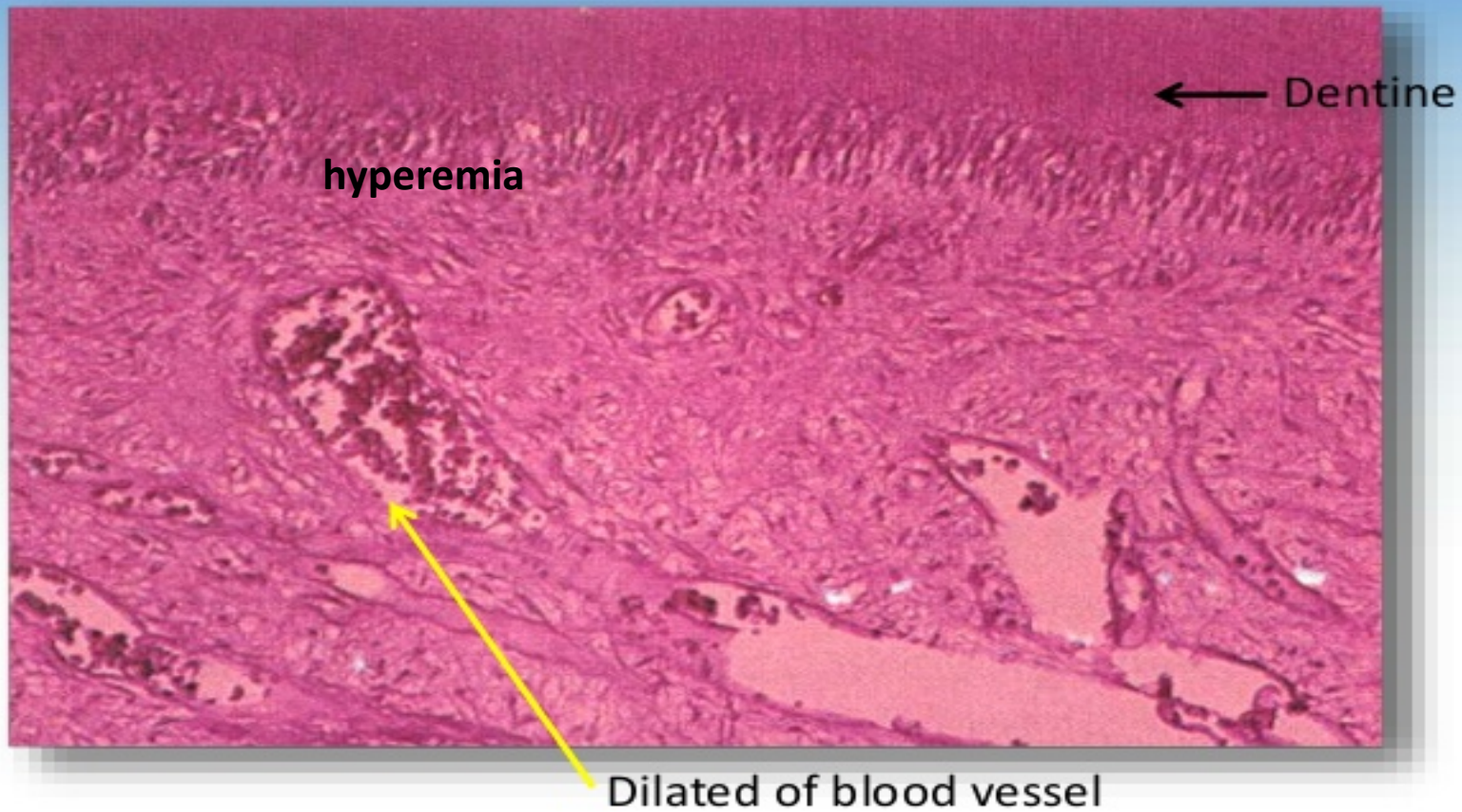

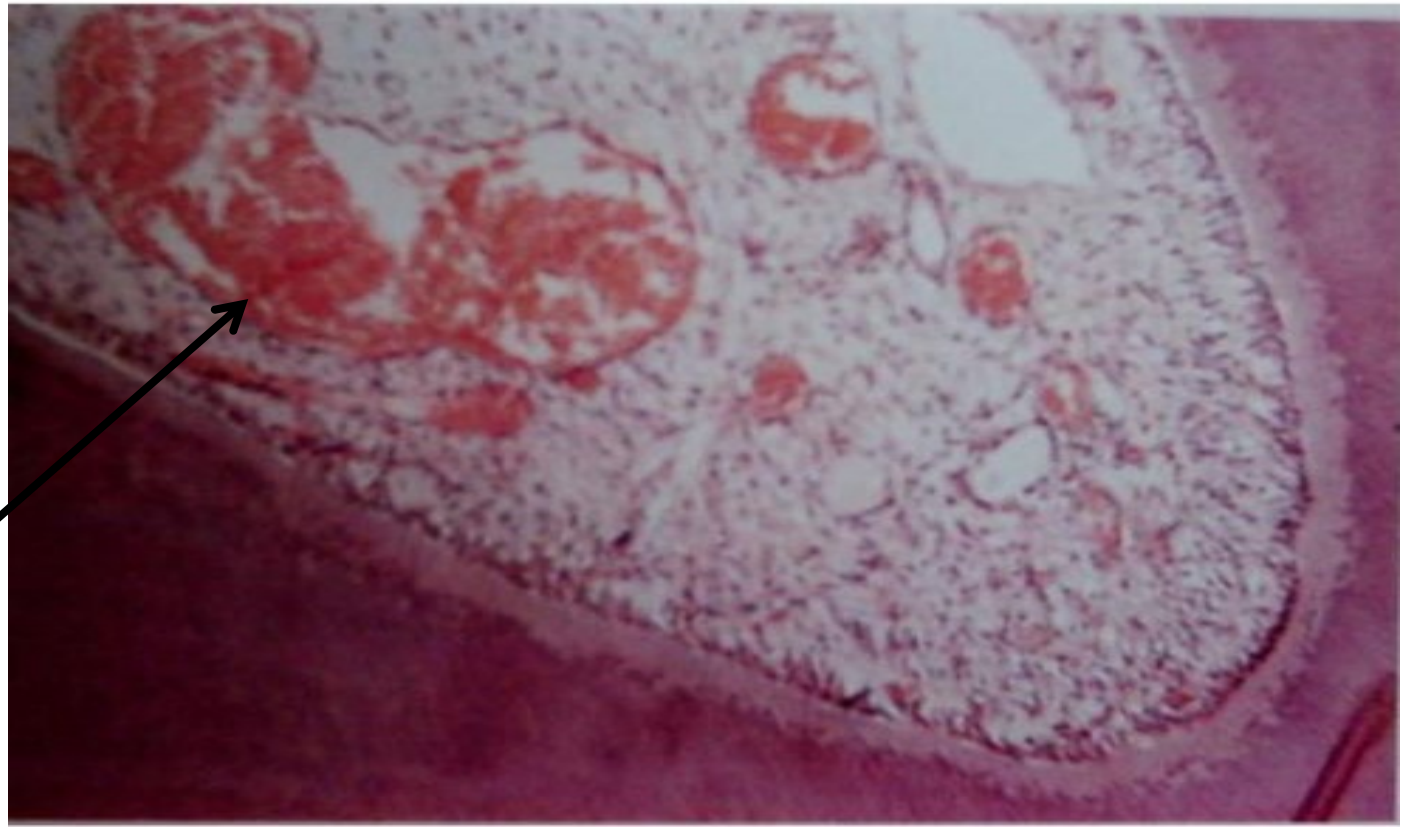

Dilated blood vessel

Irreversible pulpitis implies that a higher level of inflammation has developed in which the dental pulp has been damaged beyond the point of recovery

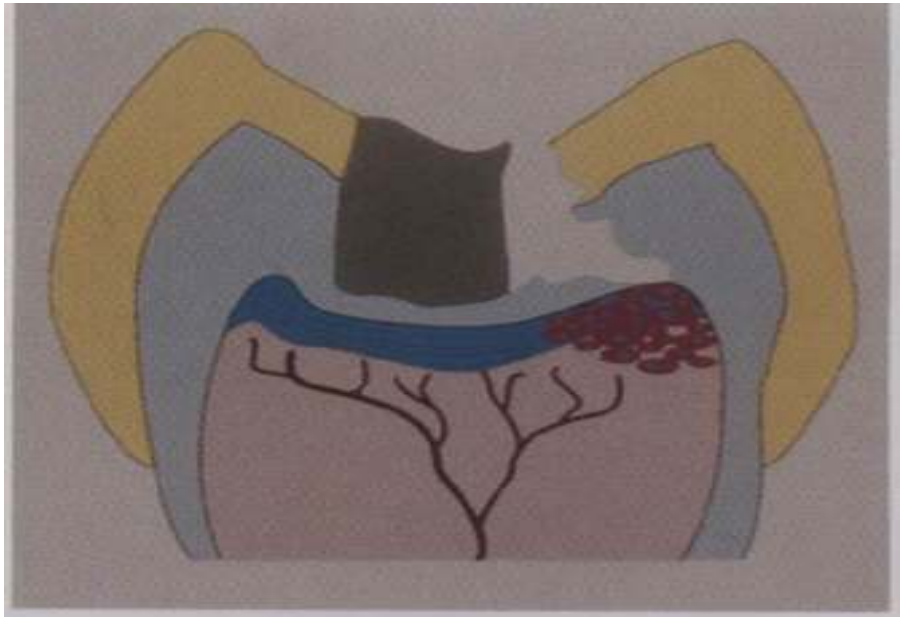

**FIGURE 3-15**

**Irreversible pulpitis.** Diagram of a focal area of acute inflammation (pulpal abscess) in a tooth with advanced recurrent caries.

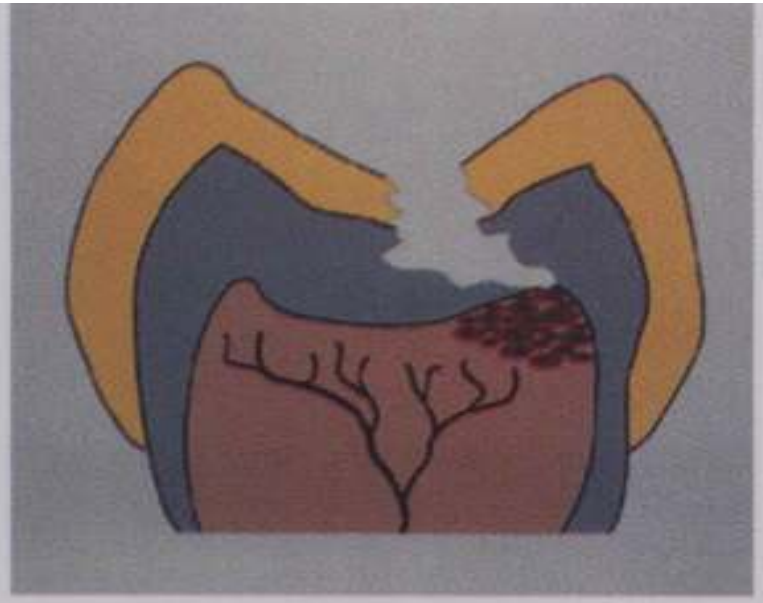

**FIGURE 3-17**

**Acute pulpitis.** Diagram of an abscess of the pulpal horn common in teeth of young patients.

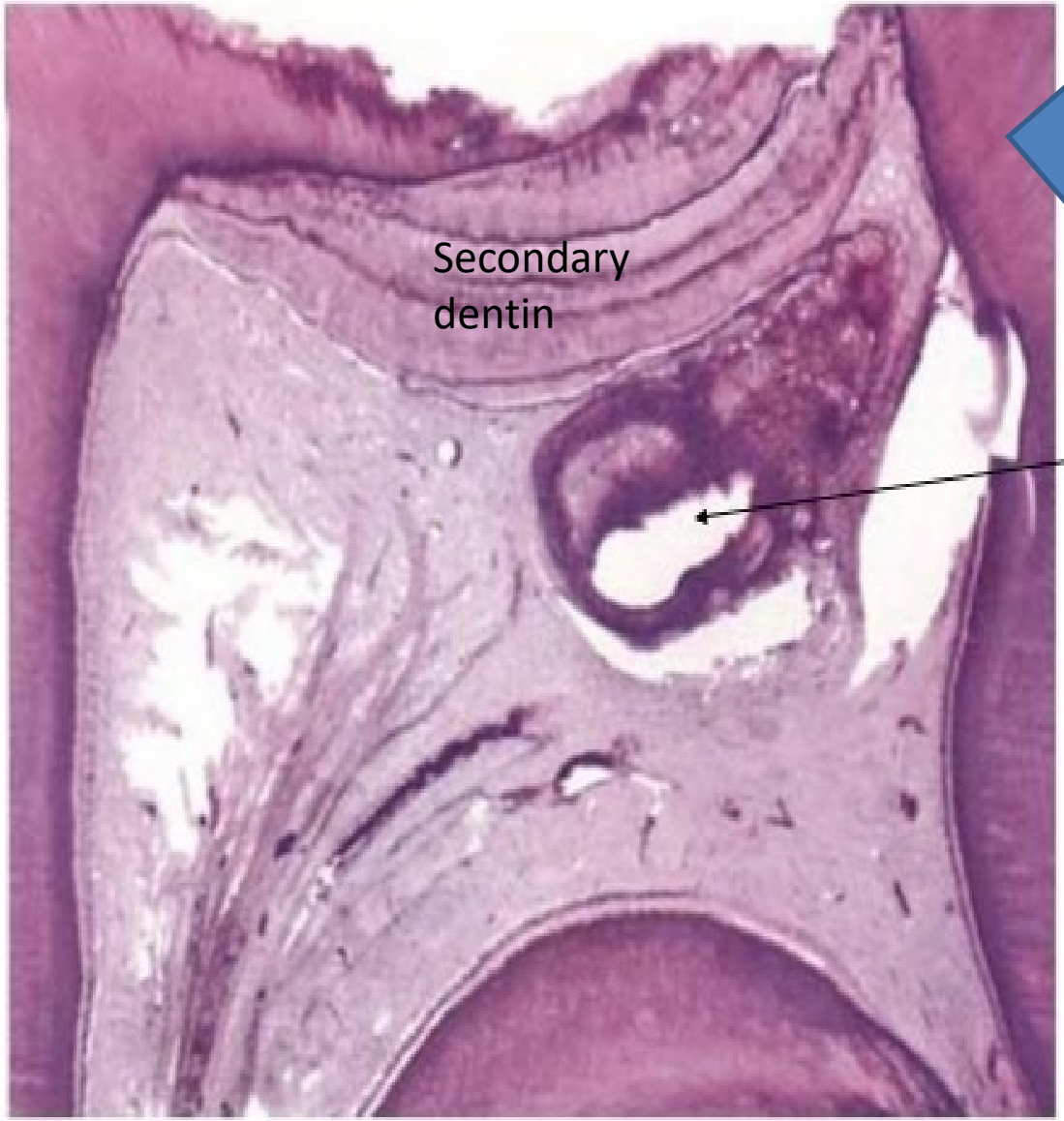
Secondary
dentin
dentin
Acute pulpitis with
Intrapulpal abscess

Increase dilation of B.V. , migration of inflammatory cells within the pulp tissue & if the inflammation persist , focal pulp abscess can be seen due to progressive accumulation of neutrophil leucocytes.

focal liquefaction necrosis
(pulp abscess)

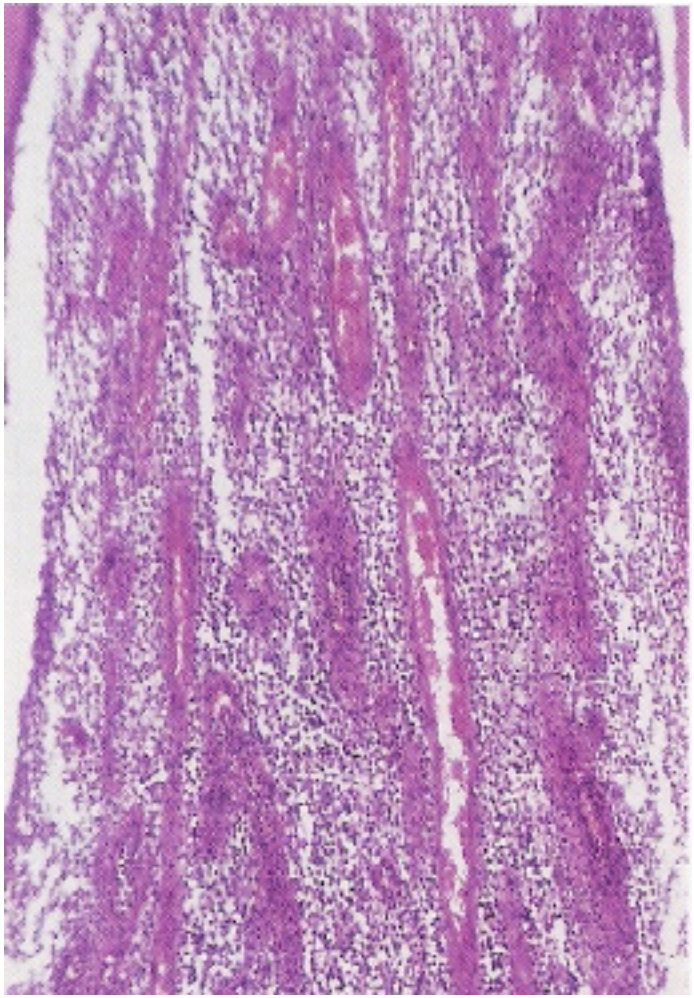

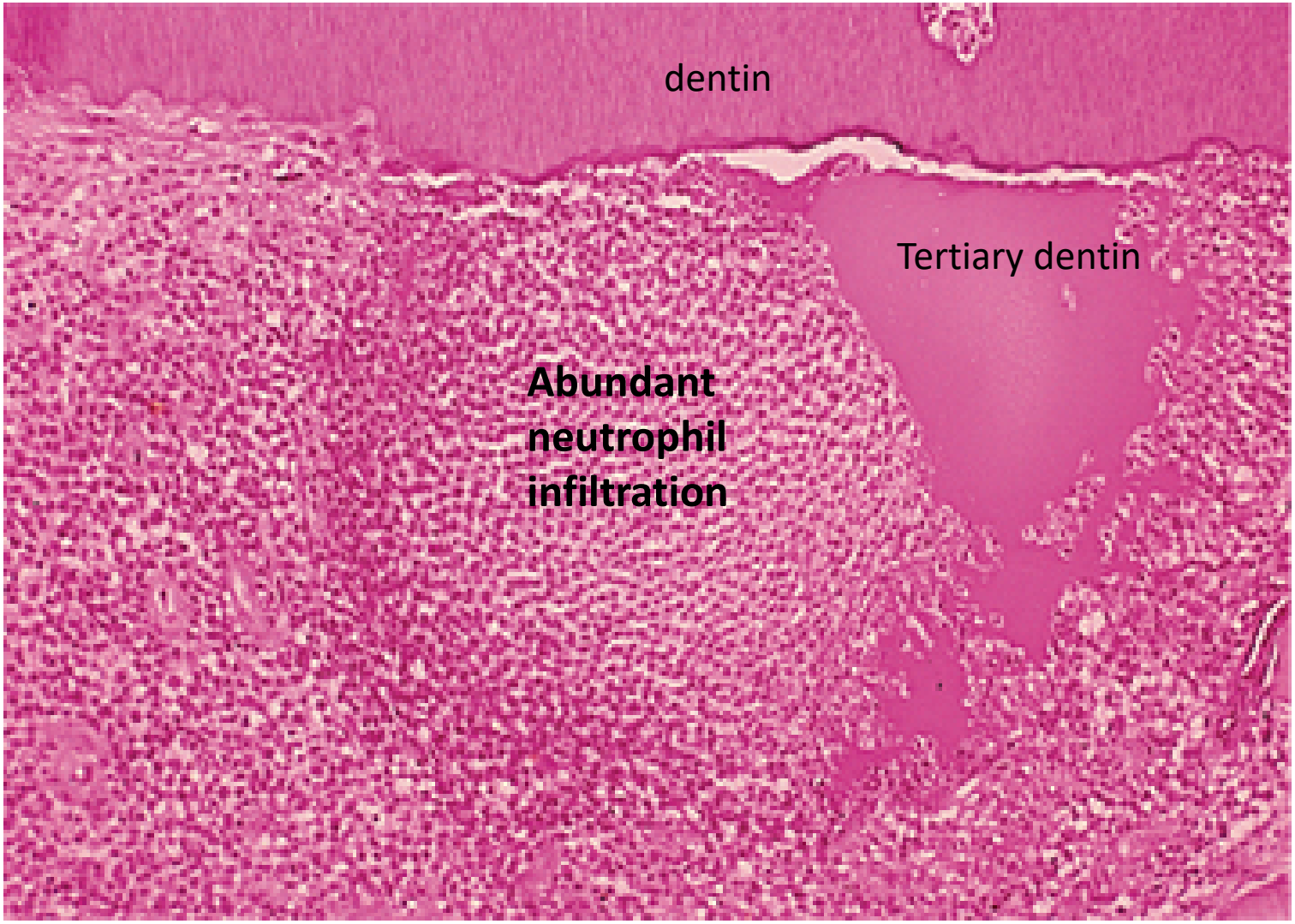


**Irreversible pulpitis**

# Chronic pulpitis

**Types of chronic inflammatory cells , mainly lymphocyte & plasma cells . also prominent capillaries & fibroblastic activity which lead to encircle area of inflammation.**

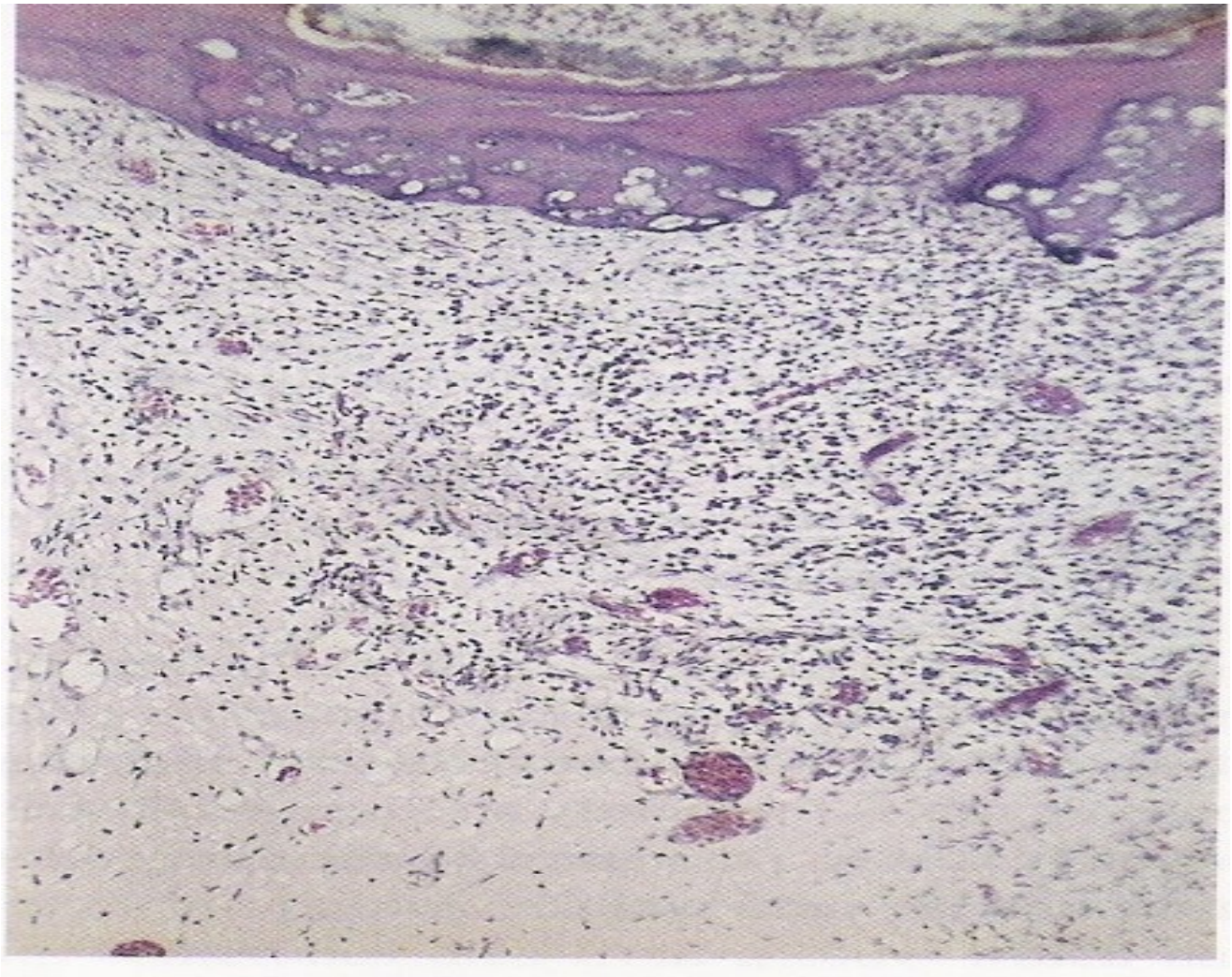

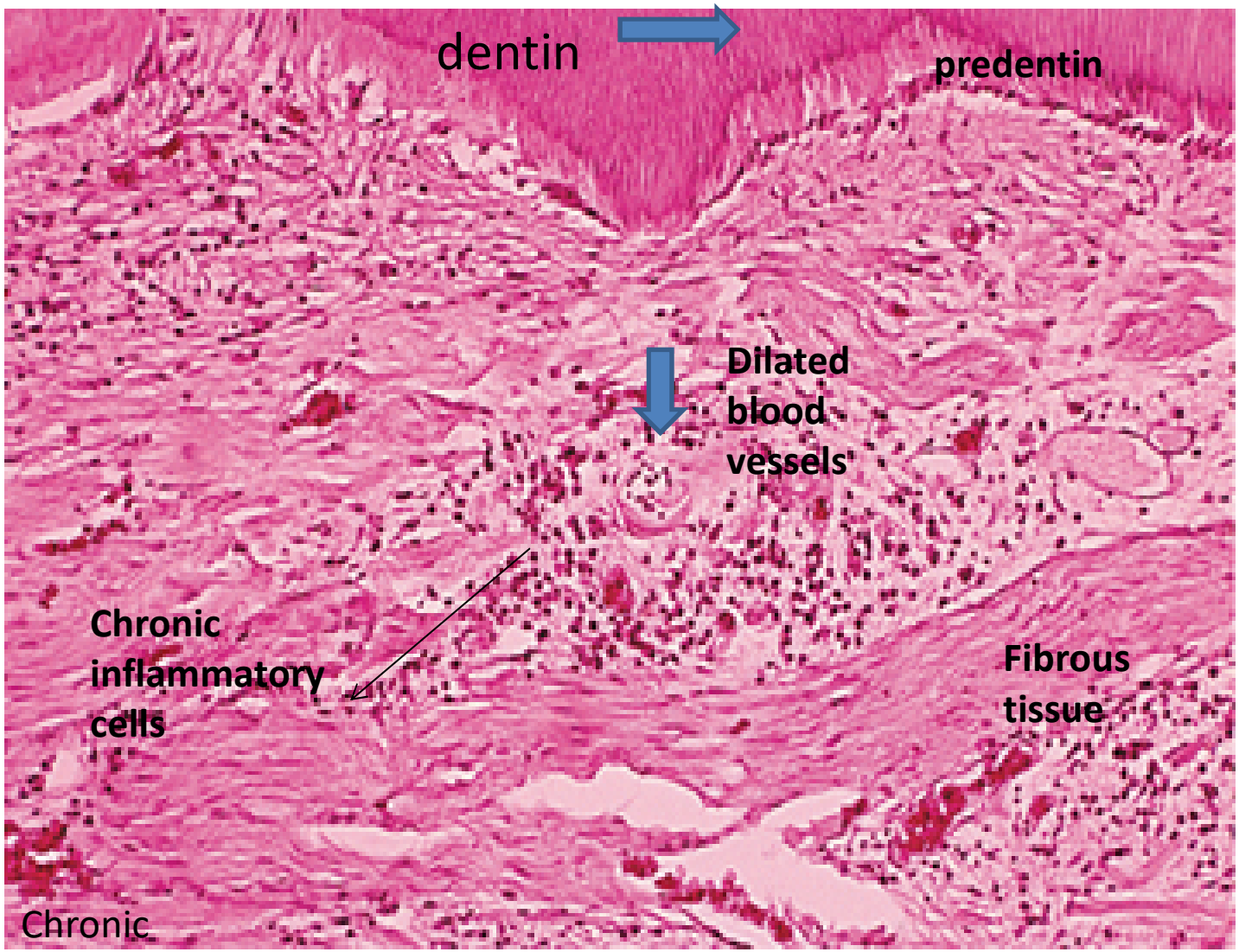


Chronic inflammation

# Pulp polyp

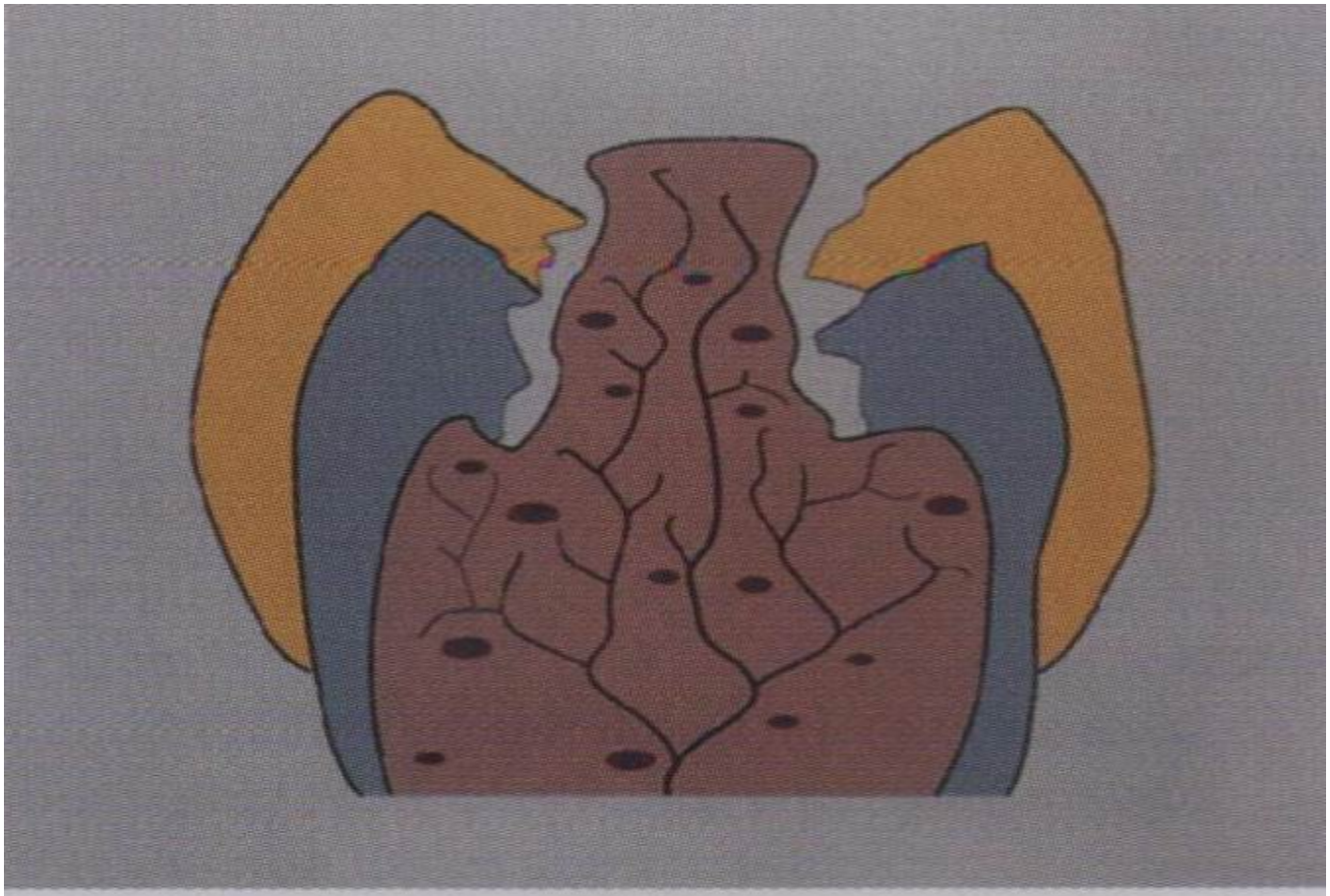

**FIGURE 3-21**

**Hyperplastic pulpitis.** Diagram of a molar in a young patient with a chronically inflamed pulp that has proliferated through the open carious defect projecting into the oral cavity.

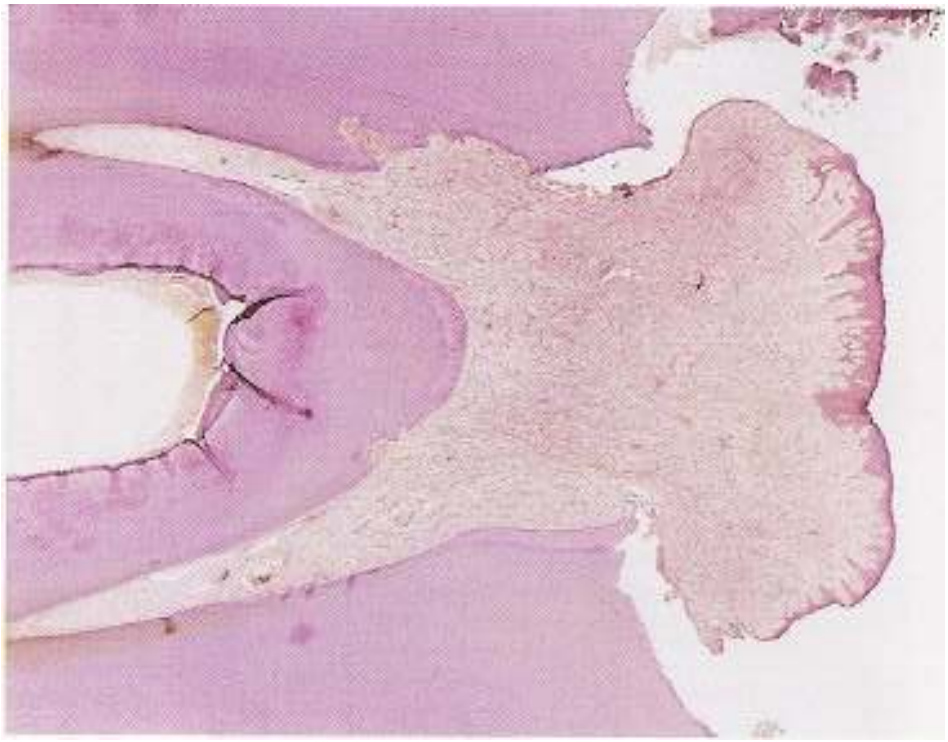

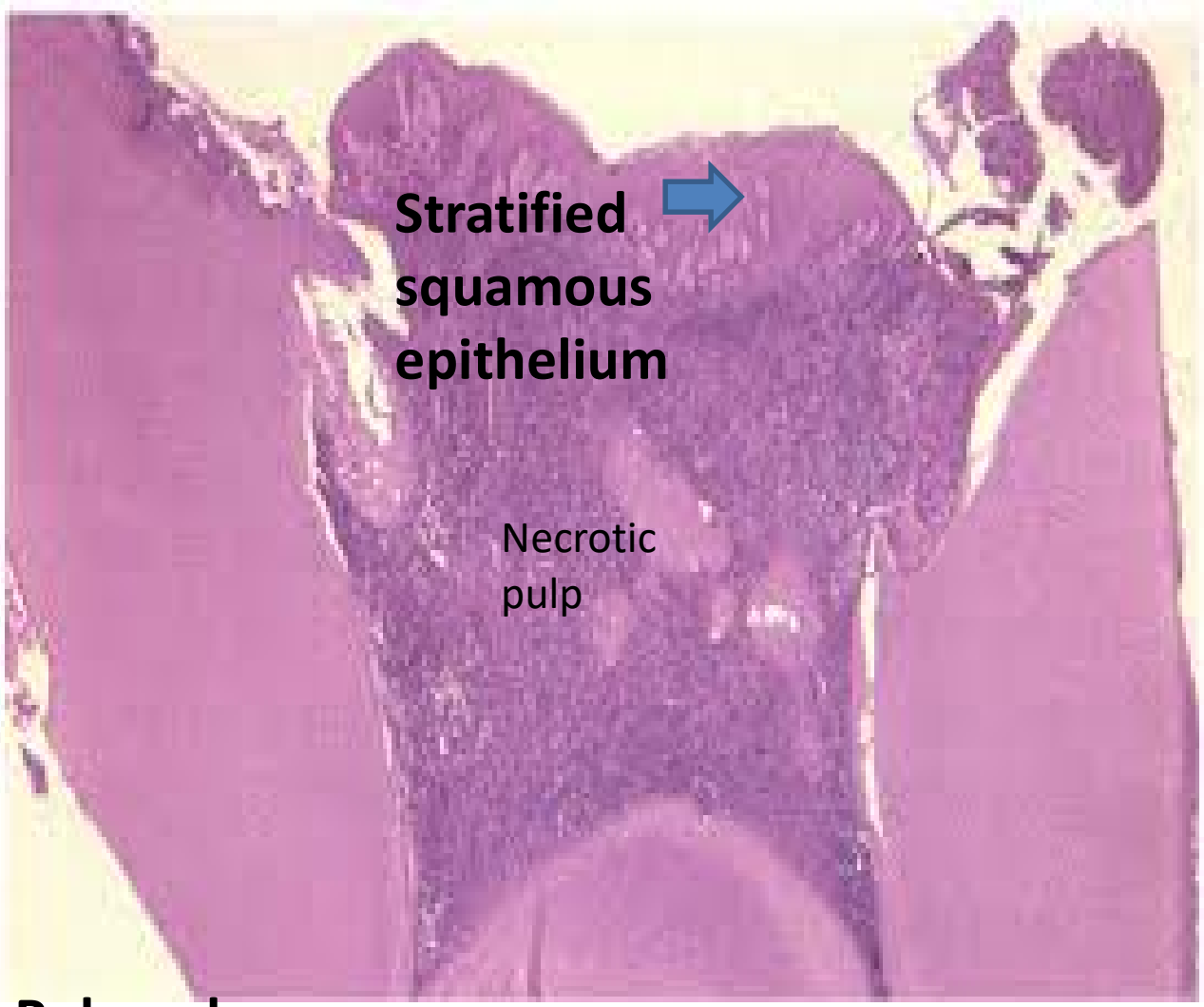


**Pulp polyp**

A

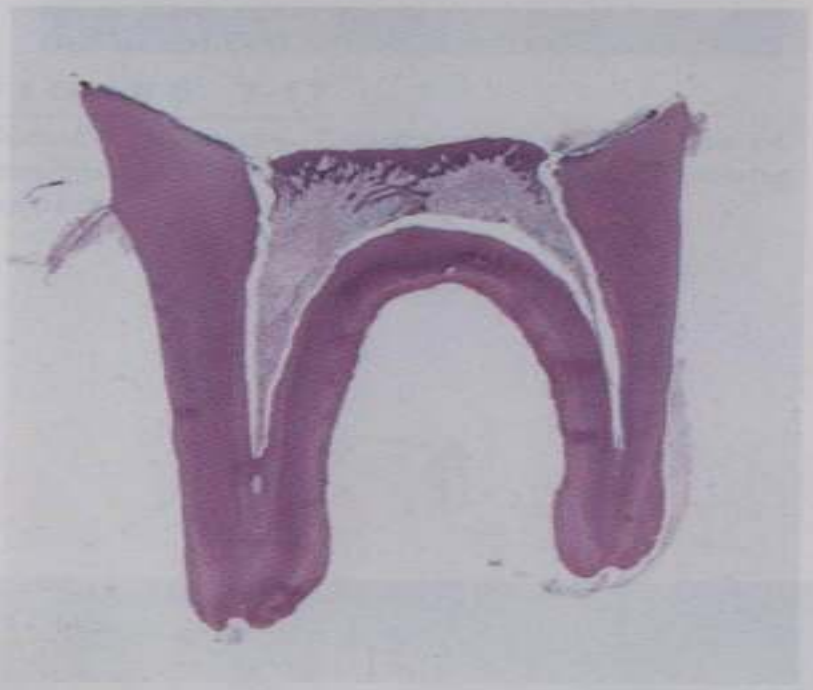

B

**FIGURE 3-22**

**Hyperplastic pulpitis. A,** Clinical appearance of "pulp polyp" in a grossly carious right mandibular first molar. **B,** Microscopic appearance of grossly carious tooth and fibrotic "pulp polyp" with a stratified squamous epithelium on the surface.

# Pulp necrosis

Non vital tooth
(pulp necrosis)

(B)

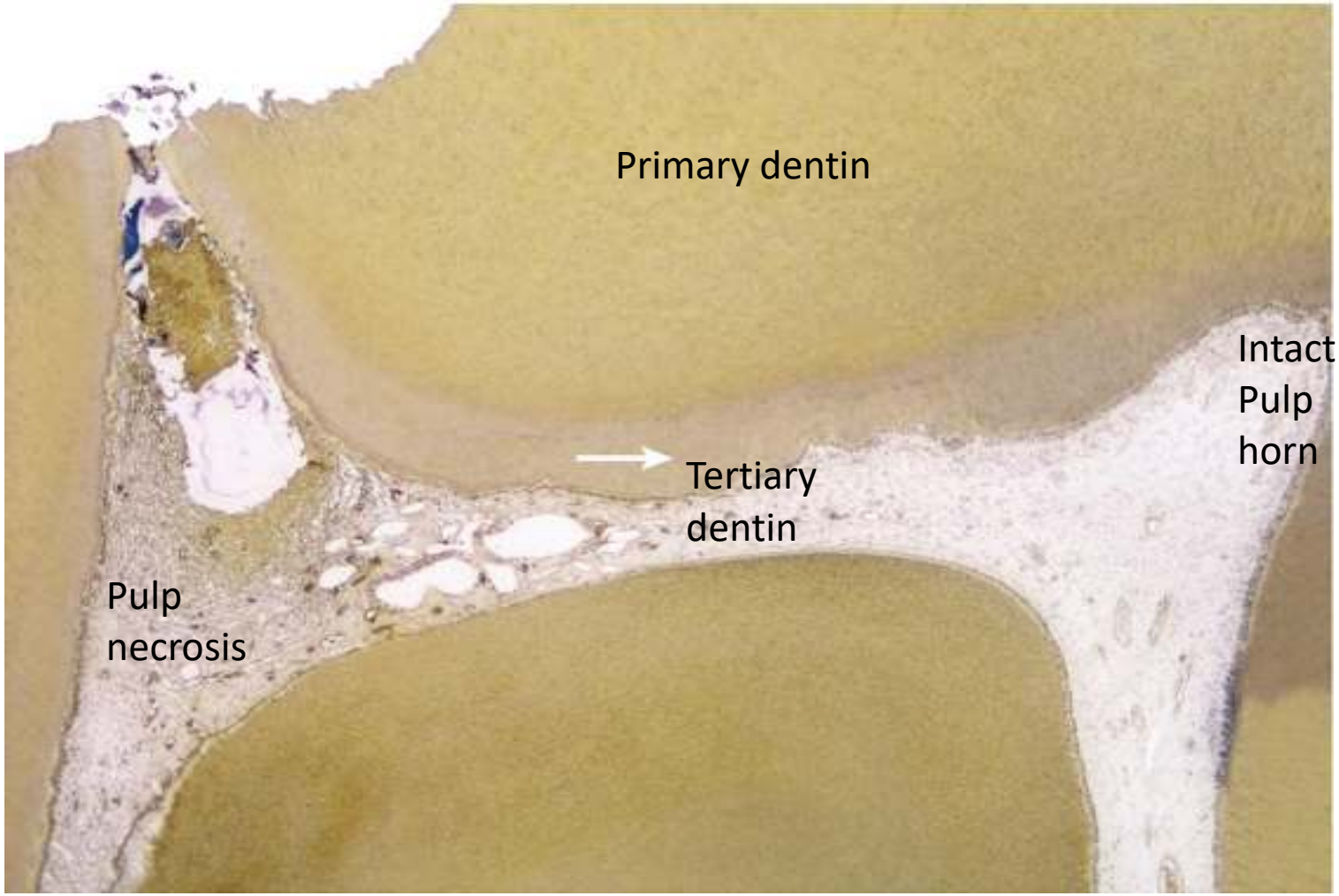
Primary dentin
Intact
Pulp
horn
Tertiary
dentin
Pulp
necrosis

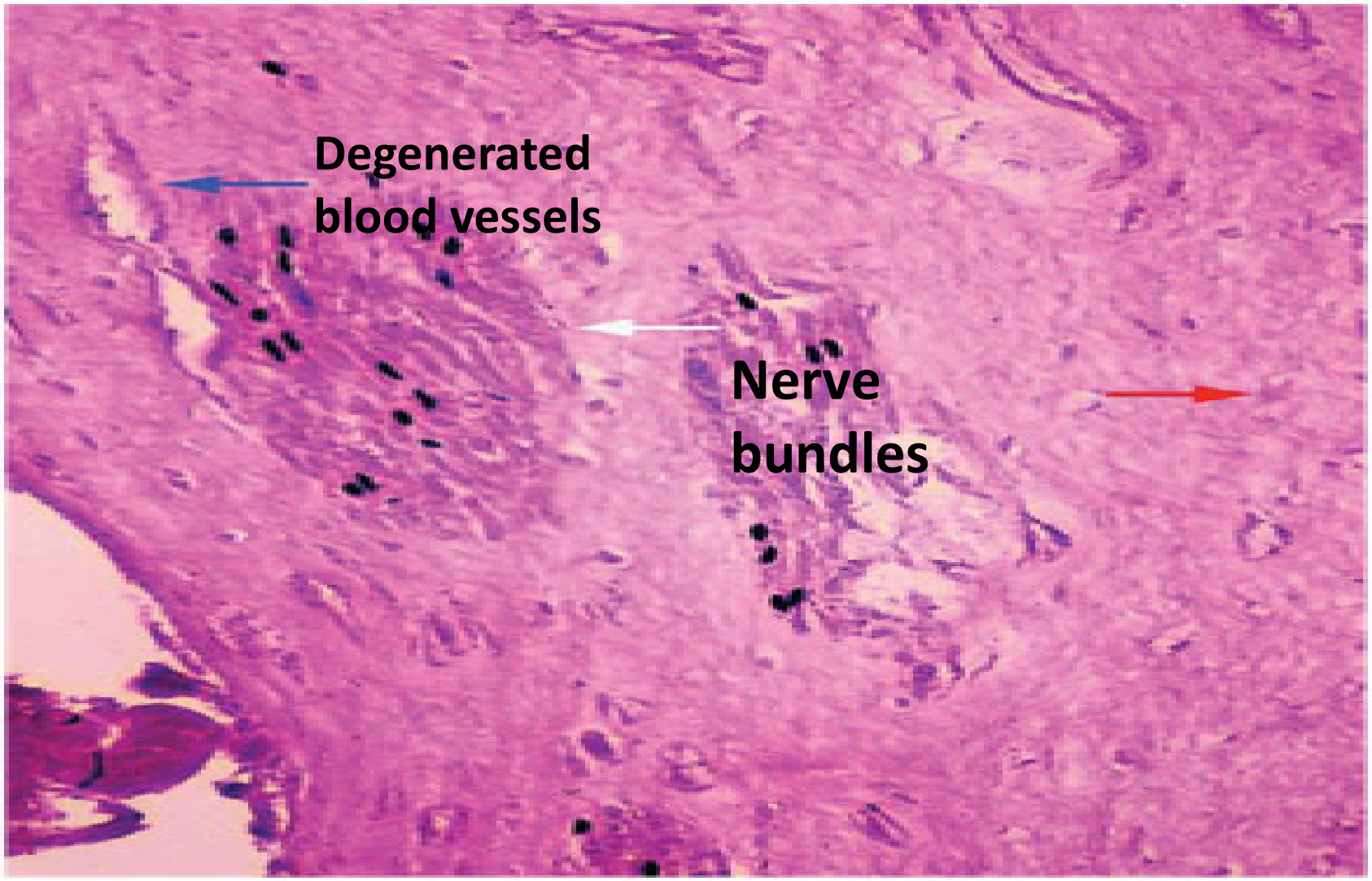


**FIGURE 3-** Pulp with complete necrosis, degeneration of blood vessels (blue arrow), cell nuclei (red arrow) and nerve bundles (white arrow) (H.E., original magnification 400X)

# Pulp stones

Pulp stone

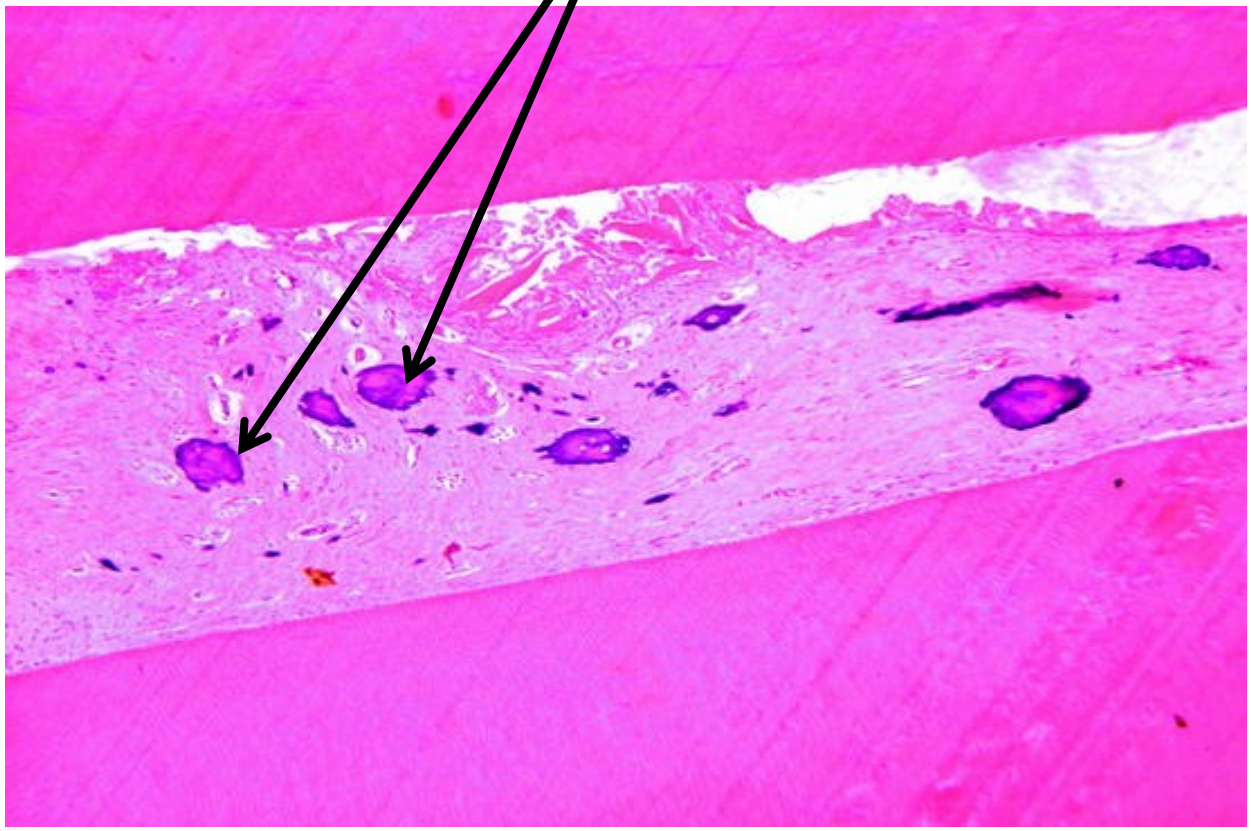

*Thank you*